



# Effect of Hesperidin on $\gamma$ -Radiation- and/or Paraquat Herbicide-Induced Biochemical, Hematological and Histopathological Changes in Rats

N.A. Abd El-Rahman,<sup>1,\*</sup> E.M. Kamal El-Dein, A.M. Abd El-Hady<sup>2</sup> and Saeed M. Soliman<sup>1</sup>

<sup>1</sup>Radiation Biology Dept., National Centre for Radiation Research and Technology, P.O. Box 29, Nasr City, Egypt.

<sup>2</sup>Faculty of Applied Medical Sciences, Misr University for Sciences and Technology, 6<sup>th</sup> October Giza, Egypt

## ABSTRACT

People are subjected to harmful effects of free radicals either from physical factors such as exposure to ionizing radiation or chemical factors due to the extensive use of herbicides in our life. The objective of this work was to investigate the possible protective effects of hesperidin (HDN) (a citrus bioflavonoid) to overcome the deleterious effects of free radicals resulting from exposure to  $\gamma$ -irradiation (IR) and/or paraquat herbicide (PQ). Male albino rats were whole body IR with 6Gy (2 Gy/week). Rats were administered HDN (40mg/Kg bwt) and/or PQ (20.8mg/kg bwt) daily by gavages during the irradiation period (3weeks). The results revealed that exposure to IR and/or PQ induced oxidative stress in blood, lung and dorsal aorta noticed by increased lipid peroxidation marker (malondialdehyde) associated with marked reduction in the content of reduced glutathione. Disturbances in serum lipid and hematology profiles were also recorded. Oxidative stress in lung and dorsal aorta was associated with histological damage. Histological changes in the lung revealed degenerative changes in the bronchiolar epithelium while damaged endothelial cells were observed. Nevertheless damages were more pronounced when rats were exposed to the combined effect of IR and PQ. The administration of HDN to rats has significantly attenuated lipids variation, reduced oxidative stress, improved blood cell counts and attenuated lung and dorsal aorta tissue injury. It could be concluded that HDN might attenuate the severity of IR and/or PQ-induced biochemical, hematological and histological damage mostly attributed to its antioxidant effect.

### Article Information

Received 6 August 2015

Revised 4 January 2016

Accepted 7 February 2016

Available online 1 August 2016

### Authors' Contribution

NAAER conceived and designed the study. NAAER, EMKED and AMAEH performed the experimental work and analyzed the data. SMS wrote the article and supervised the work.

### Key words

$\gamma$ - radiation, hesperidin, paraquat, lung, dorsal aorta, blood cells.

## INTRODUCTION

Exposure to environmental hazards including ionizing radiation, dietary factors, drugs and herbicides amongst others has urged scientists to find natural substances to protect human health. Radiation-related disorders are one of the challenging current health problems with far-reaching medical, social and economic consequences. Exposure to ionizing radiation has become inevitable since besides natural sources (cosmic rays and radioactive elements in the earth's crust) the rapid technological advancement in the field of medicine (radiotherapy and radio diagnosis), agriculture, industries, accidental and occupational exposures has increased the risk of exposure to ionizing radiation.

Paraquat (PQ) (1,1-dimethyl-4, 4- bipyridinium dichloride), is a foliar-applied and non-selective bipyridinium herbicide, and one of the most widely used in controlling weeds in a huge variety of crops. PQ, another risk to human health is highly toxic not only to plants, but also to farm animals and man (Ahmed, 2010; Abd El

Kader, 2006). Paraquat enters the body mainly by swallowing, or through damaged skin, but may also be inhaled. Thousands of deaths have occurred from ingestion (often suicide) or dermal exposure (mainly occupational). Paraquat is corrosive to the skin and once the skin is damaged it is easily absorbed into the body. Owing to its local accumulation, the lung is the primary site of its toxic effects (He *et al.*, 2012). Furthermore, chronic exposure to PQ was reported to be associated with liver damage, kidney failure, and Parkinsonian lesions in addition to fibrosis (Tanner *et al.*, 2011).

Drug exposure, ionizing radiations and environmental pro-oxidant pollutants induce free radical formation. These reactive species play a dual role in human as both toxic and beneficial compounds. At low or moderate levels, reactive species exert beneficial effects on cellular redox signaling and immune function, but at high concentrations, they produce oxidative stress, a harmful process that can damage cell function, structures and has been implicated in a number of pathological situations. The deleterious effects of these free radicals are usually repaired before mutation by two important pathways: the body's natural defense system and antioxidants consumed in the diet. Efficient defense and repair mechanisms exist in living cells to protect against oxidant species. However, under abnormal conditions

\* Corresponding author: nehad.aliibrahim@yahoo.com

0030-9923/2016/0005-1407 \$ 8.00/0

Copyright 2016 Zoological Society of Pakistan

such as exposure to ionizing radiation, the antioxidant defense system is not full operative (Sen *et al.*, 2010).

Flavonoids are polyphenolic compounds present in all foods of plant origin. They have various effects on mammalian cellular systems and structures, and have been shown to protect biological membranes against free radical-induced oxidative damage (Jain *et al.*, 2011). Hesperidin (HDN) is a flavanone glycoside abundantly found in sweet orange and lemon and is an inexpensive by-product of citrus cultivation (Manach *et al.*, 2003). HDN is effectively used as a supplemental agent in the treatment protocols of complementary settings. Its deficiency has been linked to abnormal capillary leakiness as well as pain in the extremities causing aches, weakness and night leg cramps. Supplemental hesperidin also helps in reducing oedema or excess swelling in the legs due to fluid accumulation (Akiyama *et al.*, 2010). HDN was reported to possess anticancer (Alshatwi *et al.*, 2013), health promoting effects (Li and Schluesener, 2015) and to protect against radiation-induced toxicity (Kuntić *et al.*, 2014).

The present study was designed to investigate the role of HDN against  $\gamma$ -radiation and/or paraquat induced-biochemical, hematological and histological changes.

## MATERIALS AND METHODS

### *Experimental animals*

Male albino rats Sprague Dawley (8 weeks old and 180±20 g body weight), were purchased from the Egyptian Holding Company for Biological Products and Vaccines (Helwan, Cairo, Egypt). The animals were housed under standard laboratory conditions (constant temperature 25-27°C, with 12 h light/dark cycle) during the experimental period. The rats were provided with tap water and commercial diets. Experimental animals were acclimatized to laboratory conditions for 10 days before commencement of the experiment. Drinking water and food were provided *ad libitum* throughout the study. The animal care and handling was done according to the guidelines set by the World Health Organization, Geneva, Switzerland and according to approval from the ethics committee for animals care at the National Research Centre, (ethic No.10-230).

### *Radiation treatment*

Irradiation was carried out using a Canadian Gamma Cell-40 (137Cs), located at the National Center for Radiation Research and Technology (NCRRT), Nasr City, Cairo, Egypt. The animal's whole body was exposed to gamma rays and received 6Gy administered at 2Gy/week at a dose rate 0.5Gy/minute.

### *Paraquat treatment*

Paraquat purchased from Gramoxone, Syngenta Crop Protection was diluted in water and administered daily by gavages to rats at a dose of 20.8 mg/kg body weight for 3 weeks (Abo-Shafy *et al.*, 1997).

### *Hesperidin treatment*

Hesperidin purchased from Sigma-Aldrich Chemical Company, St. Louis, MO, USA was suspended in distilled water and administered daily to rats by gavages at a dose of 40 mg/kg body weight (Hosseinimehr and Nemati, 2006) for 3 weeks. Hesperidin was prepared freshly just before its administration daily.

### *Experimental design*

Animals were divided into 8 groups of 6 rats each: Group 1 (Control): Normal healthy rats did not receive any treatment. Group 2 (HDN): Rats given hesperidin daily via gavages (40mg/kg bwt/day) for 3 weeks. Group 3 (IR): Rats whole body gamma irradiated with 6Gy administered at 2Gy/week. Group 4 (HDN+IR): Rats given hesperidin daily through the irradiation period. Group 5 (PQ): Rats given paraquat daily via gavages (20.8mg/kg bwt/day) for 3 weeks. Group 6 (HDN+PQ): Rats given hesperidin simultaneously with paraquat during 3 weeks. Group 7 (IR+PQ): Rats given paraquat daily via gavages through the irradiation period. Group 8 (HDN+IR+PQ): Rats given hesperidin and paraquat simultaneously through the irradiation period.

### *Biochemical analysis*

Rats were sacrificed on the 21<sup>st</sup> day. Rats were anaesthetized with light ether and blood samples obtained via heart puncture by sterilized syringe. A part of the blood was taken on disodium ethylene diamine tetra acetic acid (EDTA) and another part was centrifuged at 1000g for 15 min using a refrigerated centrifuge K3 Centurion Scientific Ltd, London, UK to obtain serum. Lung and dorsal aorta were rapidly excised and a 10% weight/volume (w/v) tissue homogenates were prepared in 0.1 M phosphate buffer (pH 7.4) using Teflon homogenizer Glas-Col, Terre Haute, Ind., USA. The homogenates were centrifuged at 10,000 g for 15 min and aliquots of supernatants were separated for use in the further analysis.

The lipid profile indices were determined according to standard methods. The tests included triglycerides, total cholesterol, high density lipoprotein-cholesterol content (HDL-c) and were determined according to Fossati and Principe (1982); Allain *et al.* (1974) and Demacker *et al.* (1980), respectively using a UV/VIS T60 UV/VIS spectrophotometer, PG instruments, London, UK. Low density lipoprotein-cholesterol content (LDL-

C) was determined according to the equation  $LDL-C = TC - (HDL-C + TG/5)$  (Friedewald *et al.*, 1972).

Oxidative stress markers included determination of lipid peroxidation and reduced glutathione (GSH) content. Lipid peroxidation in the blood, lung and dorsal aorta was assayed as described by Yoshioka *et al.* (1979) based on the determination of malondialdehyde (MDA) an end product of lipid peroxidation, which can react with thiobarbituric acid in acidic medium to yield a pink colored trimethine complex exhibiting an absorption maximum at 532 nm. Reduced glutathione (GSH) content was determined according to Beutler *et al.* (1963) based on the reaction of SH-groups with Ellman's reagent 5, 5'-dithiobis-2-nitro-benzoic acid to form a stable yellow color, which can be measured at 412 nm.

Assessment of hematology profile was achieved using Automated Hematology Analyzer-Model MEK-6420K, Nihon Kohden Co. Japan. Hematological indicators including erythrocyte (RBC), leukocyte (WBCs) and platelets count, hemoglobin concentration (Hb), hematocrit (Hct%), mean erythrocyte hemoglobin (MCH), mean corpuscular haemoglobin concentration (MCHC), and mean erythrocyte volume (MCV) were determined according to the method of Dacie and Lewis (2001).

#### *Histological investigations*

Samples of lung and dorsal aorta were fixed in Bouin's solution for 24 h and embedded in paraffin. Samples were serially sectioned at a thickness of 4-5  $\mu$ m using microtome (SLEE MAINZ-Cut 4050 Microtome-Lise-Meitner-Str-1-55129-Germany) and stained with hematoxylin and eosin (H&E) (Conn *et al.*, 1960). Tissue sections were examined under light microscope (Olympus-Laboratory Binocular (LED) Microscope-Model: CX23- Japan) at a magnification 400x.

#### *Statistical analysis*

The results are presented as Mean  $\pm$  Standard Error (SE) (n=6). Data were analyzed using ANOVA (one-way classification F-test) followed by Duncan (Multiple Range-test). Values were considered significant at  $P < 0.05$ .

## RESULTS

Biochemical analysis revealed that administration of HDN (40mg/kg bwt/day) by gavages daily during 3 weeks had no significant effect on lipid profile, hematology profile unless a significant decrease in MCH and MCV. The level of MDA and GSH in blood, lung and dorsal aorta showed normal values (Tables I, II and

III). No histopathological changes were observed in lung tissues and dorsal aorta (Figs. 1, 2).

The results showed also that exposure to IR and/or PQ alter lipid profile and hematology profile (Tables I and II). Meanwhile, HDN treatment reduced the increase of total cholesterol, triglycerides, and LDL-c while elevates HDL-c (Table I). Moreover, HDN adjusted WBC, RBC and Plt counts, and corrected the variations in Hb level, Hct%, MCH, MCHC and MCV (Table II).

It is observed also that exposure to IR and/or PQ significantly increased malondialdehyde (MDA) while decreased glutathione content (GSH) in the blood, lung and dorsal aorta indicating oxidative stress and increased lipid peroxidation. HDN treatment has significantly attenuated lipid peroxidation evidenced by a lower level of MDA and increased GSH content regarding respective values in rats not receiving HDN (Table III).

Examination of control lung sections showed normal architecture appearing as normal bronchial tree (bronchus, bronchioles, alveolar ducts and alveoli) and inter-alveolar septa. Bronchioles consist of mucosa, a muscle layer and a connective tissue layer. Mucosa appears as simple columnar ciliated epithelium with goblet cells which disappears as the bronchioles become smaller in diameter. The epithelium rests on a lamina propria, a continuous well developed muscle layer and a thin layer of connective tissue (Fig. 1A). Examination of control dorsal aorta sections show the wall composed of three tunics: an inner endothelial lining (tunica intima), a sub-endothelial layer (tunica media), and an outer coat (tunica adventitia) (Fig. 2A). HDN treatment had not induced any damage to lung and dorsal aorta structure (Fig. 1B and 2B).

Exposure to IR/and or PQ induced degenerative changes in the bronchiolar epithelium identified by the presence of fragments of cells and small dark nuclei, thickened edematous bronchiolar walls infiltrated with round cells, some small muscular arterioles showed medial hypertrophy in the presence of focal alveolar emphysema (Fig. 1C, E, F).. Examination of dorsal aorta sections in rats exposed to IR/and or PQ showed damaged endothelial cells (Fig. 2C, E, F). Meanwhile exposure to IR together with PQ accentuated the degenerative changes in both tissues. HDN treatment improved tissue injury resulting from exposure to IR/and or PQ (Figs. 1, 2d, F, H).

## DISCUSSION

Excess of free radicals and oxidative damage has been reported to be one of the mechanisms underlying radiation toxicity (Panganiban *et al.*, 2013) as well as paraquat (PQ) toxicity (Meng *et al.*, 2013; Hafez, 2009).

**Table I.- Influence of hesperidin (HDN) on serum lipid profile in different rat groups.**

Rat groups	Cholesterol mg/dl.	Triglycerides (mg/dl.)	LDL-c (mg/dl.)	HDL-c (mg/dl)
Control	154±1.4	265±1.7	74±0.6	28±0.13
HDN	159±1.6	273±2.8	80±0.7	24±0.28
IR	268±2.7 <sup>a</sup>	381±3.6 <sup>a</sup>	170±1.6 <sup>a</sup>	22±0.10 <sup>a</sup>
HDN+IR	199±1.9 <sup>ab</sup>	344±4.1 <sup>ab</sup>	105±1.0 <sup>ab</sup>	25±1.33 <sup>b</sup>
PQ	201±2.2 <sup>a</sup>	296±3.0 <sup>ab</sup>	110±0.9 <sup>ab</sup>	32±0.17
HDN+PQ	187±2.1 <sup>ab</sup>	286±2.1 <sup>ab</sup>	93±0.9 <sup>ab</sup>	37±1.04 <sup>a</sup>
PQ+IR	283±1.4 <sup>a</sup>	363 ±3.3 <sup>ab</sup>	181±1.7 <sup>ab</sup>	30±0.47
HDN+PQ+IR	260±2.4 <sup>ab</sup>	291±3.3 <sup>ab</sup>	163±1.0 <sup>ab</sup>	39±1.33 <sup>ab</sup>

IR,  $\gamma$  irradiated; HDN, hesperidin; PQ, paraquat.

Each value represents Mean  $\pm$  Standard Error (n=6).

<sup>a</sup>: significance vs control and <sup>b</sup>: significance vs respective IR, PQ, PQ+IR not receiving HDN at P<0.05

**Table II.- Influence of hesperidin (HDN) on hematology profile in different rat groups.**

Rat groups	WBCs 10 <sup>3</sup> / $\mu$ L	RBCs 10 <sup>6</sup> / $\mu$ L	Hb (g/dL)	Plt 10 <sup>3</sup> / $\mu$ L	Hct %	MCH (pg) Hb/RBC	MCHC (g/dL) Hb/Hct	MCV (fL) Hct/RBC
Control	7.9±0.11	5.6±0.09	14±0.6	310±3	43±1.2	25±0.8	33±1.3	77±1.8
HDN	8.4±0.19	6.6±0.07	13±0.5	286±5	38±1.4	20±0.3 <sup>a</sup>	34±0.9	58±1.1 <sup>a</sup>
IR	3.9±0.08 <sup>a</sup>	7.3±0.31 <sup>a</sup>	20±0.9 <sup>a</sup>	145±3 <sup>a</sup>	81±2.1 <sup>a</sup>	27±0.9	25±1.1 <sup>a</sup>	111±2.1 <sup>a</sup>
HDN+IR	5.2±0.10 <sup>ab</sup>	6.2±0.28 <sup>b</sup>	14±0.4 <sup>b</sup>	209±4 <sup>ab</sup>	39±0.7 <sup>b</sup>	23±0.4	36±1.6	63±1.0 <sup>ab</sup>
PQ	2.9±0.03 <sup>a</sup>	4.5±0.19 <sup>a</sup>	11±0.1 <sup>a</sup>	538±6 <sup>a</sup>	31±1.1 <sup>a</sup>	24±0.6	35±1.4	69±1.2 <sup>a</sup>
HDN+PQ	5.8±0.20 <sup>ab</sup>	5.9±0.12 <sup>b</sup>	13±0.4 <sup>b</sup>	475±5 <sup>ab</sup>	34±1.6 <sup>a</sup>	22±0.2	38±1.1	58±1.4 <sup>ab</sup>
PQ+IR	2.0±0.04 <sup>a</sup>	3.9±0.15 <sup>a</sup>	12±0.7	162±2 <sup>a</sup>	35±1.5 <sup>a</sup>	31±0.1 <sup>a</sup>	34±1.2	90±1.5 <sup>a</sup>
HDN+ PQ+IR	6.2±0.28 <sup>ab</sup>	5.9±0.18 <sup>b</sup>	12±0.5	291±4 <sup>ab</sup>	34±1.1 <sup>a</sup>	20±1.0 <sup>ab</sup>	35±1.3	58±2.4 <sup>ab</sup>

Each value represents Mean  $\pm$  Standard Error (n=6).

<sup>a</sup>: significance vs control and <sup>b</sup>: significance vs respective IR, PQ, PQ+IR not receiving HDN at P<0.05

**Table III.- Influence of hesperidin (HDN) on malondialdehyde (MDA) and glutathione (GSH) level in blood, lung and dorsal aorta of different rat groups.**

Rat groups	Blood		Lung		Dorsal aorta	
	MDA nmol/ml	GSH mg/dl	MDA nmol/g tissue	GSH mg/g tissue	MDA nmol/g tissue	GSH mg/g tissue
Control	160±1.8	56±1.2	150±2.4	22±1.1	130±1.9	148±1.2
HDN	161±1.9	55±1.6	145±2.0	21±1.1	126±1.8	152±2.1
IR	288±2.1 <sup>a</sup>	51±1.0 <sup>a</sup>	300±2.5 <sup>a</sup>	16±0.8 <sup>a</sup>	158±2.1 <sup>a</sup>	124±1.9 <sup>a</sup>
HDN+IR	164±2.1 <sup>b</sup>	54±0.9 <sup>b</sup>	200±3.0 <sup>ab</sup>	21±1.0 <sup>b</sup>	138±1.0 <sup>b</sup>	146±2.0
PQ	196±1.9 <sup>a</sup>	40±0.8 <sup>a</sup>	312±4.5 <sup>a</sup>	15±0.9 <sup>a</sup>	160±2.0 <sup>a</sup>	117±1.9 <sup>a</sup>
HDN+PQ	168±1.6 <sup>b</sup>	53±0.7 <sup>b</sup>	250±4.0 <sup>ab</sup>	20±1.2 <sup>b</sup>	128±1.9 <sup>b</sup>	152±2.1 <sup>b</sup>
IR+PQ	297±2.2 <sup>a</sup>	38±0.5 <sup>a</sup>	330±2.5 <sup>a</sup>	14±0.8 <sup>a</sup>	165±2.0 <sup>a</sup>	101±1.9 <sup>a</sup>
HDN+IR+PQ	205±2.0 <sup>ab</sup>	55±0.9 <sup>b</sup>	260±3.0 <sup>ab</sup>	20±0.7 <sup>b</sup>	132±1.9 <sup>b</sup>	148±2.0 <sup>b</sup>

Each value represents Mean  $\pm$  Standard Error (n=6).

<sup>a</sup>: significance vs control and <sup>b</sup>: significance vs respective IR, PQ, PQ+IR not receiving HDN at P<0.05

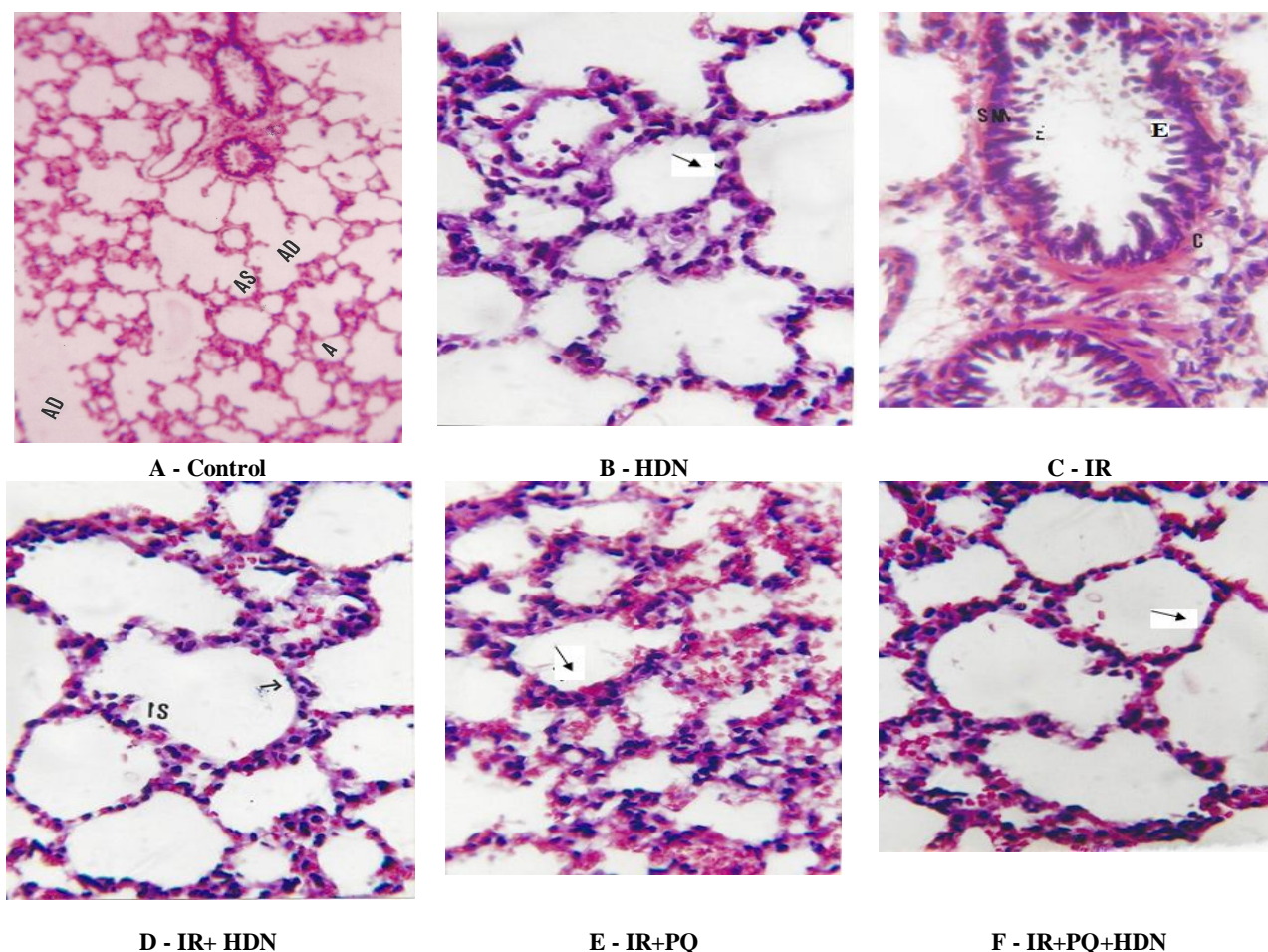


Fig.1 Histological structure of rat lung of different groups (H&E- x400)  
 A, Control rats (x 200); b, Rats given hesperidin (HDN) showing normal architecture of alveolar duct (AD) and sacs (AS); c, Rats exposed to gamma-ray (IR) showing degenerative changes in the bronchiolar epithelium (E); d, Rats exposed to IR+HDN showing regenerated smooth muscle layer of bronchiole marked thickening of the interveolar septa (IS); e, Rats exposed to IR+PQ showing severe degenerative changes in the bronchiolar epithelium (↑), mononuclear cellular infiltration of the alveolar septa, with darkly stained nuclei (↑); f, Rats exposed to IR+PQ+HDN showing apparent improvement and significant regeneration thin inter alveolar septa with almost a normal architecture (↑).

Ionizing radiation is known to generate reactive oxygen species (ROS) in irradiated tissue. Because most tissues contain 80% water, the major radiation damage is due to the aqueous free radicals, generated by the action of radiation on water. Radiation damage is caused by the overproduction of ROS including superoxide anion ( $O_2^-$ ), hydroxyl radical ( $\cdot OH$ ), and hydrogen peroxide ( $H_2O_2$ ) that overwhelm the level of antioxidants resulting in oxidative stress (Saada *et al.*, 2010; Ussama *et al.*, 2014; Hamza, and El-Shennawy, 2016) and metabolic disturbances (Saada *et al.*, 2009). In addition, radiation induces an inflammatory response which appears to be a key event

in the development of the acute radiation syndrome (Van der Meeren *et al.*, 2005).

The mechanism of PQ-induced toxicity is essentially due to its redox cycle: PQ is reduced enzymatically, mainly by NADPH-cytochrome P450 reductase (Clejan and Cederbaum 1989) and NADH:ubiquinone oxidoreductase (complex I) (Fukushima *et al.*, 1993), to form a PQ mono cation free radical with the subsequent generation of the superoxide radical ( $O_2^{\cdot-}$ ) (Dicker and Cederbaum, 1991). This then begins the well-known cascade leading to the production of other reactive oxygen species (ROS), mainly hydrogen peroxide ( $H_2O_2$ ) and hydroxyl radical ( $HO\cdot$ ).

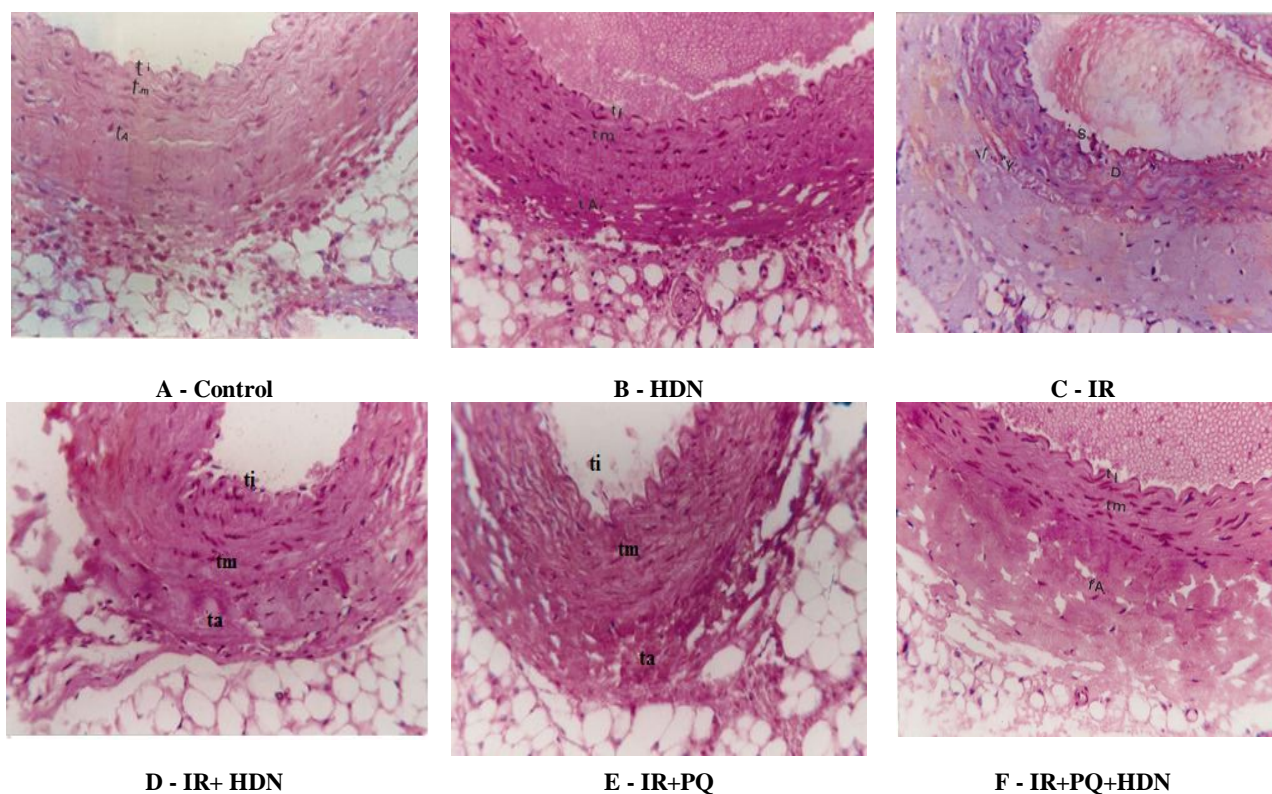


Fig. 2. Histological structure of rat dorsal aorta sections of different groups (H&E-x400). A, Control rats; B, Hesperidin-treated rat showing normal structure; C, Irradiated rats showing degeneration of endothelial cells of the tunica intima resulting in exposure of the sub endothelial tissues (s) disorganization of fibers in the tunica media vacuolization of the tunica media (v) degeneration of the inner region of tunica adventitia; d, Irradiated rats given hesperidin showing amelioration of the radiation induced changes; E, Rats exposed to irradiation and paraquat showing large degenerative regions; F, Rats exposed to irradiation and paraquat given hesperidin showing regeneration.

Lipids are a major target for free radicals and abnormal lipid profile has been established as a risk factor of coronary heart disease. In the current study, exposure to IR and/or PQ alters lipid profile evidenced by a significant increase of total cholesterol, triglyceride and LDL-c with variable changes for HDL-c relative to their respective control values. The increase of cholesterol might be attributed to lipid peroxidation causing damage to the LDL-receptor that mediates the endocytosis of LDL-c as a result, clearance of LDL-c from the circulation decreases, causing elevated blood cholesterol (Gent and Braakman, 2004). The elevated level of triglycerides is probably the consequence of inhibition of lipoprotein lipase activity or other inflammatory products that modify triglycerides metabolism indirectly (Ashry, 2010; Abd El-Gawad and Aiad, 2008). HDN treatment within the period of exposure to IR and/or PQ has attenuated hyperlipidemia supporting that HDN possesses a hypolipidemic effect (Pari *et al.*, 2015; Akiyama *et al.*, 2010) and reduces serum cholesterol and triglycerides

levels (Ashry *et al.*, 2010; Park *et al.*, 2001).

Measurement of variations in hematology profile is an important part in evaluating health status because the hematopoietic system is highly sensitive to free radicals (Cockerham and Kelman, 1988). In addition, blood cells are particularly susceptible to oxidative damage because their membranes are rich in polyunsaturated fatty acids (Meydani *et al.*, 1995). In the current study, exposure to IR and/or PQ induced variable changes in WBC, RBC, Plt, Hb, Hct%, MCH, MCHC and MCV probably resulting from oxidative stress substantiated by the significant increase of blood MDA and decreased GSH.

Exposure of rats to IR and /or PQ induced oxidative stress (elevated MDA and decreased GSH) associated with histopathological changes in the lung and dorsal aorta which were aggravated by the combined exposure to IR+PQ. The results corroborate previous findings that free radicals interact with the polyunsaturated fatty acids present in the phospholipid portion of cell membrane (Spitz *et al.*, 2004) provoking tissue injury (Soliman,

2007). Moreover, lipid peroxidation is an autocatalytic chain reaction and many of its products, are themselves very harmful to the cells (Halliwell and Gutteridge, 2004). The decrease of GSH might be due to its utilization to neutralize the excess of free radicals (Roy *et al.*, 2006).

It is well documented that antioxidants play an important role in mitigating the damaging effects of oxidative stress on tissues. In the current study, HDN treatment during exposure to IR and/or PQ has significantly decreased lipid peroxidation, and increased GSH in blood, lung and dorsal aorta. The decrease of oxidative stress in blood was associated with amelioration of the hematology profile. In the same way decreased oxidative stress in lung and dorsal aorta was accompanied by improvement of the histopathological changes in both tissues. The modulator role of HDN could be attributed to its ability to alleviate inflammation (Parhiz *et al.*, 2015) by interfering with arachidonic acid metabolism, histamine release and by inhibiting lipoxygenase, cyclooxygenase and xanthine oxidase (Berkarda *et al.*, 1998). In addition, HDN possesses antioxidant (Kalpana *et al.*, 2011) and metal chelating ability thereby inhibiting the superoxide derived Fenton reaction (Malesev and Kunti, 2007). The free radical scavenging ability (Jain *et al.*, 2011) attributed to the presence of sulphhydryl groups which react with free radicals mainly peroxynitrite (Kim *et al.*, 2004; Gaur *et al.*, 2011) and hydroxyl radical (Pradeep *et al.*, 2012) thereby contributing significantly to the intracellular antioxidant defense system (Gandhi *et al.*, 2009).

### CONCLUSION

According to the results obtained in the current study, it is concluded that hesperidin could be a useful adjunct to attenuate biochemical, hematological and histological damage induced by the over exposure to free radicals.

### ACKNOWLEDGMENT

The authors are grateful to all members in the Radiation Biology Department, National Centre for Radiation Research and Technology (NCRRT).

#### Statement of conflict of interest

Authors have declared no conflict of interest.

### REFERENCES

- Abd El-Gawad, E.I. and Aiad, S.K., 2008. Antioxidant and hypolipidemic effect of raw green snap (*Phaseolus vulgaris*) on aged male rats exposed to gamma-irradiation. *Egypt. J. Rad. Sci. Applic.*, **21**:131-144.
- Abd El Kader, M.A., Fyiad, A.A. and Soliman, M.S., 2006. Protective role of aqueous garlic extract on paraquat-induced lung injury in rats. *Egypt. J. Biomed. Sci.*, **20**: 125-136
- Abo-Shafy, A., Sakr, S., El-Saadany, M. And Abd El-Samei, H., 1997. Histological and histochemical effects of the herbicide paraquat on the liver of albino rats. *Egypt. J. Rad. Sci. Applic.*, **10**: 901-920.
- Ahmed, M.M., 2010. Radio and chemo protective properties of hesperidin against genotoxicity induced by gamma radiation and/or paraquat in rat bone marrow cells. *Egypt. J. Rad. Sci. Applic.*, **23**:233-244.
- Akiyama, S., Katsumata, S., Suzuki, K.M., Ishimi, Y., Wu, J. and Uehara, M., 2010. Dietary hesperidin exerts hypoglycemic and hypolipidemic effects in streptozotocin-induced marginal type 1 diabetic rats. *J. Clin. Biochem. Nutr.*, **46**:87-92.
- Allain, C.C., Poon, L.S., Chan, C.S., Richmoud, W. and Fu, P.C., 1974. Enzymatic determination of total serum cholesterol. *Clin. Chim.*, **20**: 470-475.
- Alshatwi, A.A., Ramesh, E., Periasamy, V.S. and Subash-Babu, P., 2013. The apoptotic effect of hesperetin on human cervical cancer cells is mediated through cell cycle arrest, death receptor, and mitochondrial pathway. *Fundam. Clin. Pharmacol.*, **27**: 581
- Ashry, O.M., Kafafy, Y.A. and El Tawil, G.A., 2010. Influence of hesperidin on lipid metabolism, oxidative stress and related trace elements in  $\gamma$ - irradiated rats. *Egypt. J. Rad. Sci. Applic.*, **23**:15-28.
- Berkarda, B., Koyuncu, H., Soybir, G.T. and Baykut, F., 1998. Inhibitory effect of hesperidin on tumor initiation and promotion in mouse skin. *Res. Exp. Med.*, **198**: 93-99.
- Beutler, E., Duron, O. and Kelly, B.M., 1963. Improved method for determination of blood glutathione. *J. Lab. Clin. Med.*, **61**:882 – 888.
- Clejan, L. and Cederbaum, A.I., 1989 Synergistic interaction between NADPHcytochrome P-450 reductase, paraquat and iron in the generation of active oxygen radicals. *Biochem. Pharmacol.*, **38**:1779–1786.
- Cockerham, L. and Kelman, B., 1988. Summary of symposium on acute radiation- induced injury. *Fundam. Appl. Toxicol.*, **11**:571-2.
- Conn, H.J., Darrow, M.A. and Emmels, V.M ,1960. *Staining procedures used by the biological stain commission*, 2<sup>nd</sup> Edition, The Williams & Wilkins Co. Baltimore, pp 93-94,
- Dacie, J.V. and Lewis, S.M., 2001. In: *Practical hematology* 10<sup>th</sup> Ed Churchill Livingstone.
- Demacker, P.N., Vos-Janssen, H.E., Hifman, A.G., Vants Lear, A. and Jansen, A.P., 1980. Measurement of high density lipoprotein cholesterol in serum: Comparison of six isolation methods combined with enzymatic cholesterol analysis. *Clin. Chem.*, **26**:1780-1787.

- Dicker, E. and Cederbaum, A.I., 1991. NADH-dependent generation of reactive oxygen species by microsomes in the presence of iron and redox cycling agents. *Biochem. Pharmacol.*, **42**:529–535.
- Fossati, P. and Prencipe, L., 1982. Enzymatic determination of triglycerides *Clin. Chim.*, **28**: 2077-2080.
- Friedewald, W.T., Levy, R.T. and Frederickson, D.S., 1972. Estimation of the concentration of low-density lipoprotein cholesterol in plasma without use of the preparative ultracentrifuge. *Clin. Chem.*, **18**: 499-502.
- Fukushima, T., Yamada, K., Isobe, A., Shiwaku, K. and Yamane, Y., 1993. Mechanism of cytotoxicity of paraquat. I. NADH oxidation and paraquat radical formation via complex I. *Exp. Toxicol. Pathol.*, **45**:345–349.
- Gandhi, C., Upaganalawar, A. and Balaraman, R., 2009. Protection against *in vivo* focal myocardial ischemia/reperfusion injury-induced arrhythmias and apoptosis by hesperidin. *Free Rad. Res.*, **43**:817 – 827.
- Gaur, V., Aggorwal, A. and Kumar, A., 2011. Possible nitric oxide mechanism in the protective effect of hesperidin against ischemic perfusion cerebral injury in rats. *Indian J. exp. Biol.*, **49**: 608-618.
- Gent, J. and Braakman, I., 2004. Low-density lipoprotein receptor structure and folding. *Cell Mol. Life Sci.*, **61**: 2461–2470.
- Hafez, A.M., 2009. Antigenotoxic activity of melatonin and selenium against genetic damage induced by paraquat. *Aust. J. Basic & Appl. Sci.*, **3**: 2130-2143
- Hamza, R.G. and El-Shennawy, H.M. 2016. Study of the influence of Egyptian apple against oxidative stress in gamma-irradiated rats. *Pakistan J. Zool.*, **48**: 547-556.
- Halliwell, B. and Gutteridge, J.M.C., 2004. *Free radicals in biology and medicine*. 3<sup>rd</sup> Ed. Oxford University Press Inc, New York.
- He, X., Wang, L., Szklarz, G., Bi, Y. and Ma, Q., 2012. Resveratrol inhibits paraquat- induced oxidative stress and fibrogenic response by activating the nuclear factor erythroid 2-related factor 2 pathway. *J. Pharmacol. Exp. Ther.*, **342**:81-90
- Hosseinimehr, S.J. and Nemati, A., 2006. Radio protective effects of hesperidin against gamma irradiation in mouse bone marrow cell. *Br. J. Rad.*, **79**,415-418.
- Jain, D.P., Pancholi, S.S. and Patel, R., 2011. Synergistic antioxidant activity of green tea with some herbs. *J. Adv. Pharm. Technol. Res.*, **2**: 177-183.
- Kalpana, K.B., Devipriya, N., Srinivasan, M., Vishwanathan, P., Thayalan, K. and Menon, V.P., 2011. Evaluating the radioprotective effect of hesperidin in the liver of Swiss albino mice. *Europ. J. Pharmacol.*, **658**:206 – 212.
- Kim, D.H., Jung, E.A., Sohng, I.S., Han, J.A., Kim, T.H. and Han, M.J., 1998. Intestinal bacterial metabolism of flavonoids and its relation to some biological activities. *Arch. Pharmacol. Res.*, **21**: 17–23.
- Kuntić, V., Brborić, J., Holclajtner-Antunović, I. and Uskoković-Marković, S., 2014. Evaluating the bioactive effects of flavonoid hesperidin – A new literature data survey. *Vojnosanit Pregl.*, **71**:60-65.
- Li, C. and Schluesener, H., 2015. Health-promoting Effects of the Citrus Flavanone Hesperidin. *Crit. Rev. Fd. Sci. Nutr.*, **12**:0. [Epub ahead of print]
- Malesev, D. and Kunti, V., 2007. Investigation of metal-flavonoid chelates and the determination of flavonoids via metal-flavonoid complexing reactions. *J. Serb. Chem. Soc.*, **72**:921–939.
- Manach, C, Morand, C., Gil-Izquierdo, A., Bouteloup-Demange C. and Remesy, C., 2003. Bioavailability in humans of the flavanones hesperidin and narirutin after the ingestion of two doses of orange juice. *Eur. J. Clin. Nutr.*, **57**:235–42.
- Meng, X.X., Wang, R.L., Gao, S., Xie, H., Tan, J.T. and Qian, Y.B., 2013. Effect of ulinastatin on paraquat-induced-oxidative stress in human type II alveolar epithelial cells. *World J. Emerg. Med.*, **4**:133-7
- Meydani, S.N., Wu, D., Santos, M.S. and Hayek, M.G., 1995. Antioxidants and immune response in aged persons: overview of present evidence. *Am. J. Clin. Nutr.*, **62**: 1462S-1476S.
- Panganiban, R.M., Snow, A.L. and Day, R.M., 2013. Mechanisms of radiation toxicity in transformed and non-transformed cells: *Int. J. Mol. Sci.*, **14**: 15931–15958.
- Parhiz, H., Roohbakhsh, A., Soltani, F., Rezaee, R. and Iranshahi, M., 2015. Antioxidant and anti-inflammatory properties of the citrus flavonoids hesperidin and hesperetin: an updated review of their molecular mechanisms and experimental models. *Phytother. Res.*, **29**:323-331.
- Pari, L., Karthikeyan, A. and Karthika, P., 2015. Protective effects of hesperidin on oxidative stress, dyslipidaemia and histological changes in iron-induced hepatic and renal toxicity in rats. *Toxicol. Rep.*, **2**: 46–56
- Park, Y.B., Do, K.M., Bok, S.H., Lee, M.K., Jeong, T.S. and Choi, M.S., 2001. Interactive effect of hesperidin and vitamin E supplements on cholesterol metabolism in high cholesterol –fed rats. *Int. J. Vitam. Nutr. Res.*, **71**: 36.
- Pradeep, K., Ko, K.C., Choi, M.H., Kang, J.A., Chung, Y.J. and Park, S.H., 2012. Protective effect of hesperidin, a citrus flavanoglycone, against  $\gamma$ -radiation-induced tissue damage in Sprague-Dawley rats. *J. Med. Fd.*, **15**:419-427.
- Roy, W., Maya, K., Shawn, M., Larry, L., Christine, D. and Basil, J., 2006. Dynamic responses of the glutathione system to acute oxidative stress in dystrophic mouse (mdx) muscles. *Am. J. Physiol. Regul. Integr. Comp. Physiol.*, **291**: 704-710.
- Saada, H.N., Rezk, R.G. and Eltahawy, N.A., 2010. Lycopene protects the structure of the small intestine against gamma-radiation-induced oxidative stress. *Phytother. Res.*, **24** Suppl 2:S204-8.
- Saada, H.N., Said, U.Z., Mahdy, E.M., Elmezayen, H.E. and Shedid, S.M., 2014. Fish oil omega-3 fatty acids reduce



- the severity of radiation-induced oxidative stress in the rat brain. *Int. J. Radiat. Biol.*, **90**: 1179-1183.
- Saada, H.N., Said, U.Z., Meky, N.H. and Abd El Azim, A.S., 2009. Grape seed extract *Vitis vinifera* protects against radiation-induced oxidative damage and metabolic disorders in rats. *Phytother. Res.*, **23**:434-8.
- Soliman, S.M., 2007. Protecstive role of oregano oil against histological changes in whole body gamma irradiated albino rats. *J. Egypt. Ger. Soc. Zool.*, **52C**: 46-56.
- Sen, S., Chakraborty, R., Sridhar, C., Reddy, Y. and De Biplab, 2010. Free radicals, antioxidants, diseases and phytomedicines: current status and future prospect. *Int. J. Pharmaceut. Sci. Rev. Res.*, **3**: 91-100.
- Spitz, D.R., Azzam, E.I., Li, J.J. and Gius, D., 2004. Metabolic oxidation/reduction reactions and cellular responses to ionizing radiation: A unifying concept in stress response biology. *Cancer Metast. Rev.*, **23**: 311-322.
- Tanner, C.M., Kamel, F., Ross, G.W., Hoppin, J.A., Goldman, S.M., Korell, M., Marras, C., Bhudhikanok, G.S., Kasten, M. and Chade, A.R., 2011. Rotenone, paraquat, and Parkinson's disease. *Environ. Hlth. Perspect.*, **119**:866-872.
- Ussama, Z.S., Neamat, H.A., Amina, M.M. and Mustafa, M.M., 2014. Effects of omega-3 fatty acids against Ehrlich carcinoma-induced hepatic dysfunction. *J. Cancer Res. Exp. Oncol.*, **6**: 20-28.
- Van der Meeren, A., Monti, P., Vandamme, M., Squiban, C., Wysocki, J. and Griffiths, N., 2005. Abdominal radiation exposure elicits inflammatory responses and obscopal effects in the lungs of mice. *Rad. Res.*, **163**: 144-152.
- Yoshioka, T., Kawada, K., Shimada, T. and Mori, M., 1979. Lipid peroxidation in maternal and cord blood and protective mechanisms against activated oxygen toxicity in the blood. *Am. J. Obstet. Gynecol.*, **135**: 372-376.